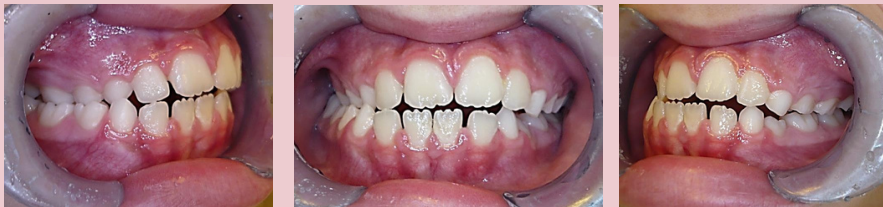
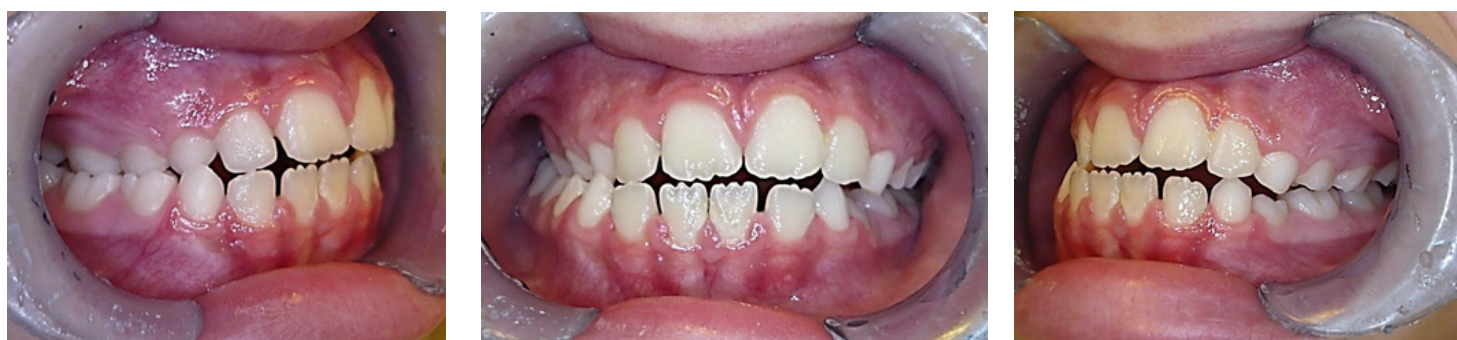
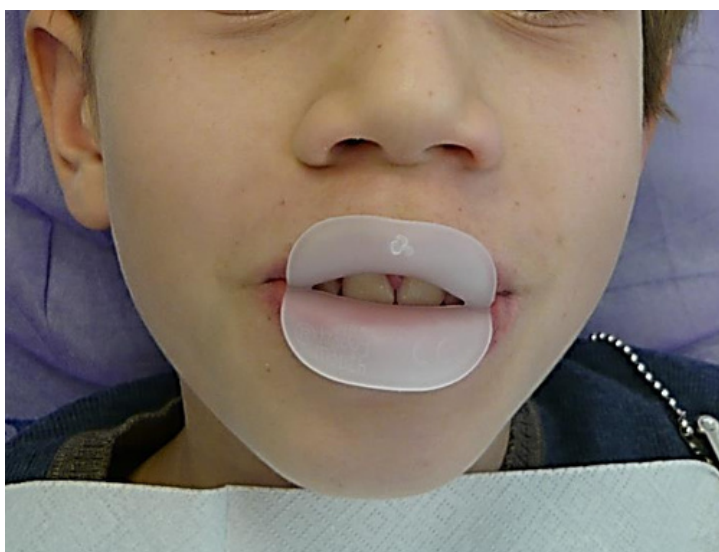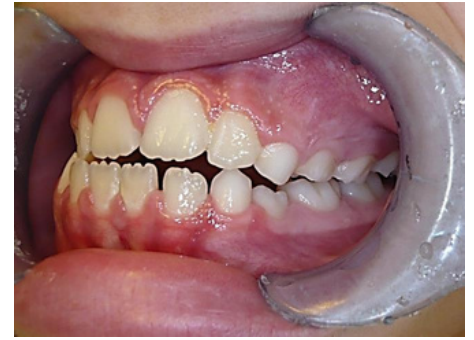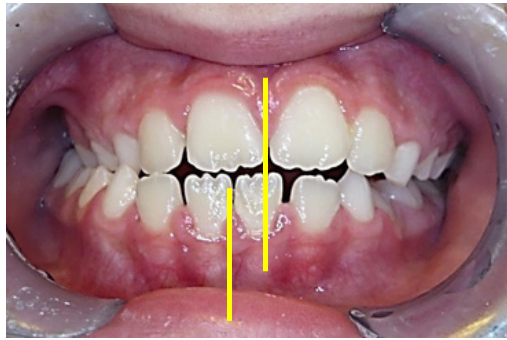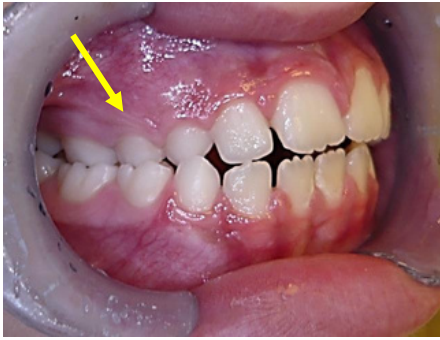
**RIGHT CROSSBITE**  
Dr. Pietro Manzini



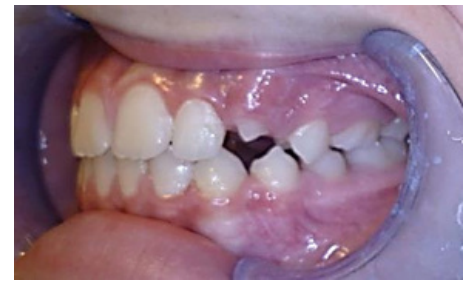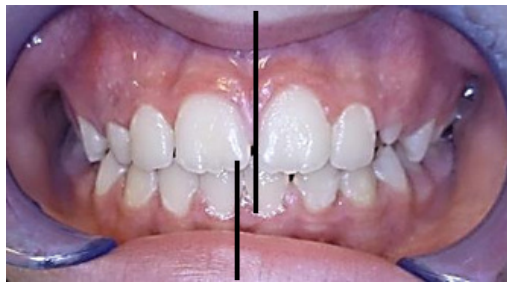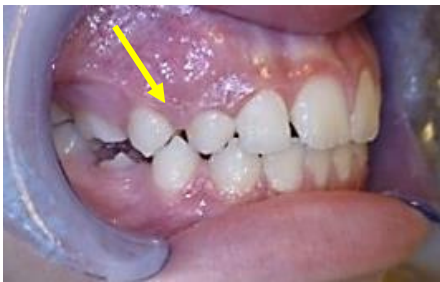THE 11-YEAR-OLD MALE PATIENT PRESENTS A RIGHT CROSSBITE AND A  
"SUCTION-SWALLOWING" SWALLOWING PATTERN.  
THE USE OF FROGGMOUTH IS PRESCRIBED.



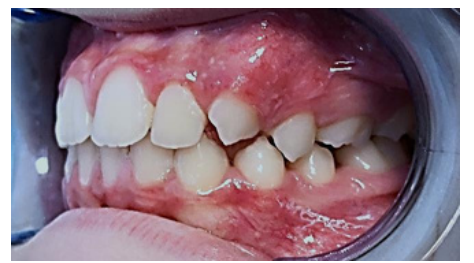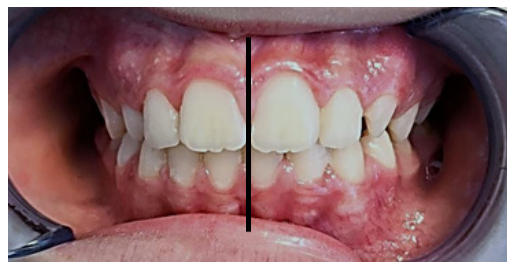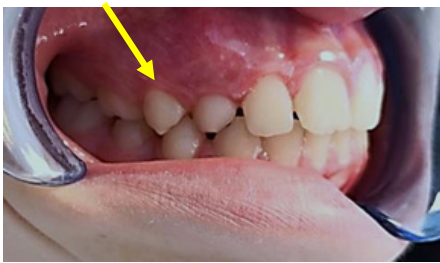START OF TREATMENT



10 MONTHS LATER



15 MONTHS LATER



AFTER 10 MONTHS, THE TREATMENT WITH FROGGYMOUTH IS COMPLETED:  
THE ATYPICAL SWALLOWING PATTERN HAS BEEN CORRECTED, AND THE  
CROSSBITE HAS STARTED TO REGRESS.

DURING THE FOLLOWING 5 MONTHS, THE OCCLUSION NATURALLY  
CORRECTED ITSELF.



FROGGYMOUTH